


## Supplementary oxygen and wound healing



**Author:**  
Sonia Silvestrini

Chronic non-healing wounds are an increasing problem worldwide, with the costs of managing these posing challenges clinically, socially and economically. The association between oxygen and wound healing is well established and it is known that a sustained oxygen deficit has a detrimental impact to patients with chronic wounds. Recent advancements in new technology to deliver oxygen therapy directly to the wound bed are being applied to an increasing number of wounds. This article examines the role of oxygen and options for delivery, with a focus on NATROX® Oxygen Wound Therapy in wound healing. It reviews the impact of the use of Natrox in delivering oxygen to the wound and the benefits this has on wound healing in two patients with chronic, non-healing, lower-limb ulceration.

**T**he prevalence and incidence of wounds continues to be a growing issue worldwide, particularly in countries experiencing an ageing population, which is often associated with increased comorbidities. Furthermore, lifestyle choices can compound complications witnessed in common disease types, such as the development of wounds in peripheral arterial disease and diabetes (Jarbrink et al, 2016; Sen, 2019).

In developed countries, wound care accounts for approximately 3% of total healthcare expenditure (Posnett and Franks, 2008). It is estimated that the prevalence of wounds across Europe is affecting 1.5–2m people at any one time (Lindholm and Searle, 2016). Hence, it is imperative that with such high therapy costs and the sheer number of sufferers, the wound care offered needs to be optimised.

Successful wound healing relies on an accurate diagnosis, which should then determine appropriate treatments that address the underlying cause. A recent Italian study categorised the prevalence of lower-limb ulceration and the main aetiology of these were 55% venous, 25% arteriovenous and 8% diabetic; these are all known to have a detrimental impact on the perfusion of tissue (Apollonio et al, 2016).

Another Italian study analysed patients who had been discharged from hospital with a chronic wound. While the percentages were different — 71% were diabetic foot ulcers, 17% were leg

ulcers and 8% were pressure ulcers (Ragno et al, 2018) — what was consistent was the underlying small vessel disease, which is often seen in these wound types.

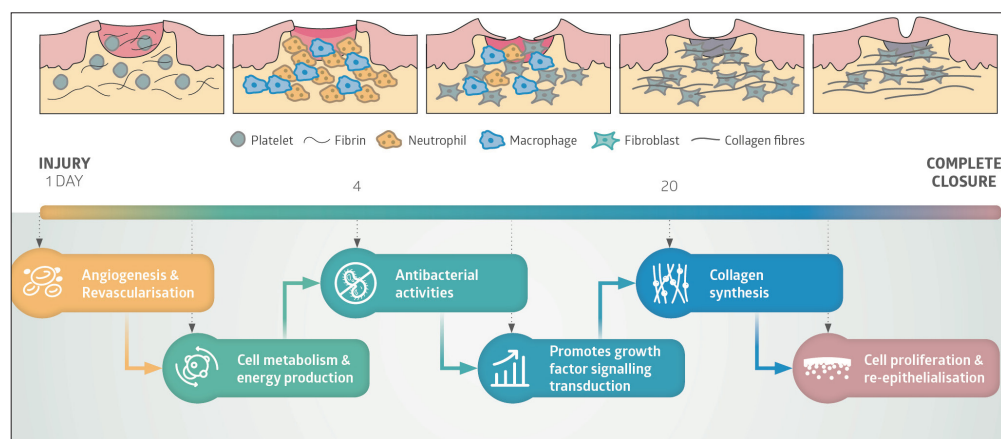
It is well recognised that oxygen is an essential element during all aspects of wound healing and while all wounds will experience some level of hypoxia, wounds where small vessel disease is present suffer from substantial and prolonged hypoxia, making them a challenge for clinicians to manage.

Temporary hypoxia occurs after tissue injury and triggers wound healing; however, prolonged or chronic hypoxia delays the continuing wound healing process (Bishop, 2008; Rodriguez et al, 2008). In the acute phase, hypoxia serves as a signal to stimulate many aspects of the wound-healing process (the normal sequence of events is summarised in *Figure 1*). It can induce cytokine and growth factor production from macrophages, keratinocytes and fibroblasts, which are crucial promoters of cell proliferation, migration and chemotaxis, and angiogenesis (Rodriguez et al, 2008). The demand for, and utilisation of, oxygen increases when there is tissue damage and as oxygen is not stored within the tissues, it is important there is an adequate and continuous supply to damaged tissues for repair and wound healing to take place (Howard et al, 2013).

Tissue repair requires an increase in energy, which is supplied from the metabolism of glucose that occurs in the presence of oxygen to produce

*Sonia Silvestrini is Wound Care Specialist Head Nurse, Internal Medicine, San Giovanni Addolorata Hospital, Rome, Italy*

**Figure 1.** Oxygen requirements for cellular and wound healing processes throughout all the stages of wound healing.



adenosine triphosphate (ATP). Decreased levels of oxygen available impact on the cellular resources available to aid wound healing (Kimmel, 2016).

Continued hypoxia increases the production of reactive oxygen species (ROS) to a level that exceeds the beneficial effect and causes additional tissue damage. A wound that fails to heal in a timely manner due to prolonged hypoxia becomes a chronic wound. It is, therefore, not surprising that increasing oxygen delivery to wounds has been reported to improve wound healing and tissue repair.

### Oxygen therapy

Oxygen therapy in wound care is not a new concept. For many years, hyperbaric chamber (HBOT) has been used to deliver 100% oxygen, systemically at high pressures with the aim of increasing the wound oxygen level to above normal physiological levels. However, as this is systemic and not direct to the wound, it is reliant on adequate blood perfusion to transport the oxygen via the arterial system (Smith et al, 1996); this may explain the inconclusive evidence when used on patients with peripheral arterial disease or micro-vascular disease as a result of diabetes, (Gottrup and Apelqvist, 2012; Kranke et al, 2015).

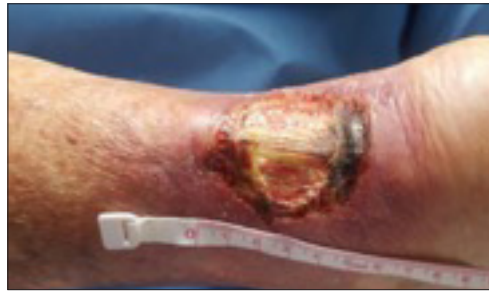There are also significant risk factors to be taken into account, such as toxicity, seizures and barotrauma etc, which is why treatment sessions are restricted to 90-minute sessions, five days a week. Other limitations include access to a unit and the high costs related to this therapy (Winfield, 2014).

Intermittent pressurised topical oxygen therapy was developed to try and tackle some of these issues. Frye et al (2010) reported improved wound healing, with increased vascular endothelial growth factor (VEGF) expression and angiogenesis, reduction of infection and pain along with a reduction in ulcer recurrence. The system delivers pressurised topical oxygen,

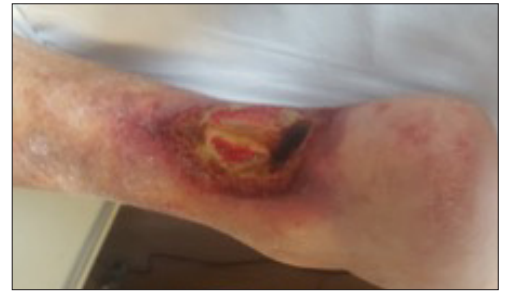slightly above atmospheric pressure, at a high flow rate to the wound using large pressurised cylinders connected to a chamber or bag that surrounds the anatomical region of the wound. This creates an oxygen-rich environment, which allows the diffusion of oxygen into the wound tissue (Howard et al, 2013; Winfield, 2014). Treatment periods vary from 90 minutes up to 4 hours a day, three to five days a week. The advantage of this treatment over HBOT is decreased costs and patient risks. Unfortunately, the therapy is still intermittent and generally requires the patient's attendance at a specialist clinic or unit.

Newer technologies now enable the provision of continuous topical oxygen to be delivered directly to a wound bed at normospheric pressure. The therapy is more portable, user friendly and offers a more cost-effective solution to HBOT, or pressurised topical oxygen therapy (Howard et al, 2013). The device administers topical oxygen directly to the wound bed at a lower rate than HBOT or a localised chamber, and the relatively small size of the device employed for generating and delivering the oxygen makes it portable and lightweight. This enables use of the device on a continuous basis without restricting the patients' activities of daily living and offers cost effectiveness against HBOT. This new system reports fewer risks and side effects (Howard et al, 2013) and is able to deliver a continuous supply of oxygen to the wound at low flow rates without the need for pressure.

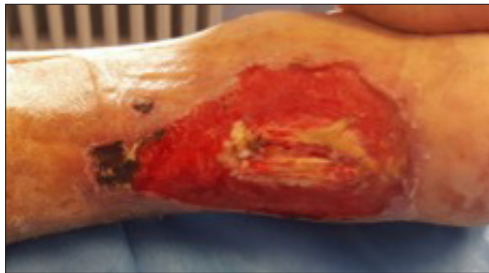Due to the reported patient and clinical benefits of this type of device, it was selected for use in two patients with some significant challenges relating to small vessel disease. Both patients discussed in this article were treated with an innovative therapy called NATROX® Oxygen Wound Therapy (Inotec), which consists of a small battery-powered 'oxygen generator' (OG), which delivers approximately



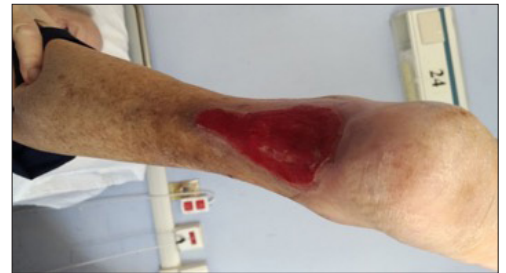*Figure 2. Two-year-old left achilles tendon ulcer.*



*Figure 3. Ulcer following NPWT, some improvement noted, however, patient unable to tolerate due to pain.*



*Figure 4. Day 14 of Natrox therapy commenced, increase in size of ulcer however healthier tissue now present.*



*Figure 5. Day 35 of Natrox therapy, tendon now covered with granulation tissue.*

13 ml of humidified oxygen per hour through a fine bore soft tube to a disposable Oxygen Delivery System (ODS). This is placed directly over the wound and held in place by a conventional dressing. The NATROX device is completely portable as it uses rechargeable and interchangeable batteries, which supply enough power to generate oxygen for a full 24 hours.

### Case study 1

An 82-year-old retired male physician who remains very active on a social level, presented with ulceration over his left achilles tendon, which had been present for 2 years. The injury was initially caused by his shoe rubbing and creating frictional damage. Despite the obvious trauma, he continued to wear the offending shoes until the situation deteriorated and he had a very painful non-healing ulcer. The patient was also known to have venous insufficiency and had previously been non-concordant with treatment.

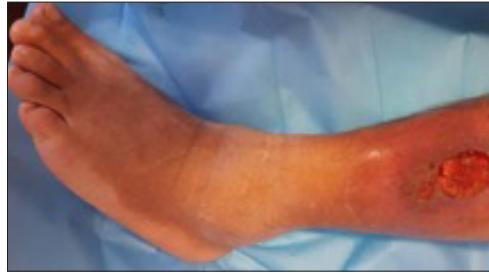
On presentation, the ulcer measured 4 cm x 5 cm with exposed tendon evident [Figure 2]. The wound bed was predominately unhealthy with over 50% slough and 30% necrotic, particularly at the lower aspect of the wound. The patient reported high levels of pain (10 on the visual analogue scale) for which he was taking regular morphine that neither improved or eliminated the pain. The wound showed clinical signs of infection with high levels of purulent malodorous exudate.

There had been an attempt to heal the ulcer with various other treatments from his medical colleagues (betadine solution and surgical debridement), however, this only ever caused deterioration of the wound. Negative Pressure Wound Therapy (NPWT) was commenced and the wound initially became larger, which is not unexpected where unhealthy tissue is the predominant tissue type. There was improvement to the tissue type [Figure 3] but unfortunately, the patient was unable to tolerate the device due to increased pain.

NPWT was discontinued and the patient was commenced on NATROX Oxygen Wound Therapy, with the intention of reducing both the clinical signs of infection and pain levels, while moving towards a healing trajectory.

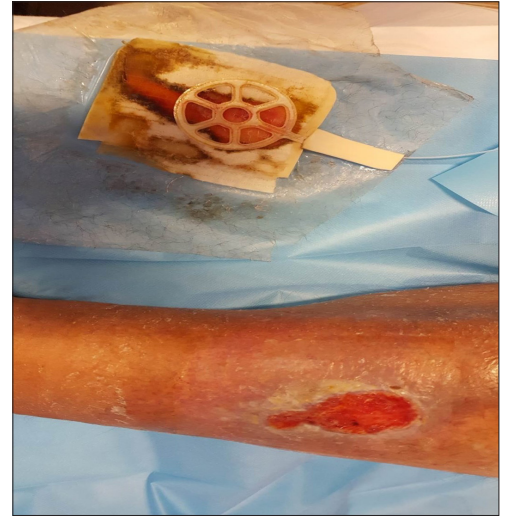The oxygen delivery system (ODS) was applied directly to the ulcer (white side down) with a hydrofiber applied as a secondary dressing for absorbency. The dressing was secured in place with a crepe bandage. Within the first 12 hours of the therapy the patient reported a complete resolution of his pain and no longer required his opioid analgesia. The first dressing change occurred after 48 hours of commencing the therapy and then every 4 days after. By day 14 [Figure 4], the ulcer was predominately free from any necrotic tissue and the wound bed comprised 85% healthy granulation tissue.

As expected with this type of therapy, the ulcer initially became larger, as a result of the autolytic debridement process. This occurs as the oxygen



*Figure 6 (above). Two-and-a-half-year-old venous leg ulcer, prior to Natrox therapy.*

*Figure 7 (right). Day 20 of Natrox therapy — ulcer larger but healthier appearance.*



optimises cellular activity resulting in enhanced neutrophil and macrophage activity, which engulf the pathogens and debride the devitalised tissue.

At day 35 [Figure 5], there was 100% healthy granulation tissue evident across the whole of the ulcer bed with the tendon completely covered and islands of epithelialisation noted both in the centre of the wound and around the edges.

At this point, the patient chose not to continue with NATROX as he felt the ulcer had healed enough and it could be managed with standard wound dressings. Clinically, it was felt that the wound would have benefited from ongoing oxygen therapy and would have completely closed in another 10–14 days of therapy, however, as with all medical care, it is important to respect and support the wishes of the patient.

NATROX exceeded the patient's expectations in terms of pain relief and infection. The patient's pain was monitored every 4 hours initially using a visual analogue scale, and within 12 hours, the pain had reduced to 0 from its highest level and remained at 0 for the duration of the therapy. The patient reported that he had slept properly for the first time in many months, which significantly enhanced his overall wellbeing.

The improvement in the ulcer enabled the patient to regain some of his independence and he was able to re-establish his involvement in organising charity events. Although complete healing was not achieved, this 2-year-old wound was now on a positive healing trajectory. While the use of analgesics is a fundamental component of managing wound pain, the associated side effects can be problematic. Having the ability to discontinue opioids due to his wound pain being resolved was viewed as particularly beneficial. The simple application and management of the device was also a positive aspect of this therapy; facilitating collaboration between clinicians and

patients will often improve concordance, clinical outcomes and quality of life for the patient and NATROX certainly delivered in this respect.

## Case study 2

Case study 2 involves a 48-year-old male with a 2.5-year history of a venous ulcer on his left leg, lateral aspect of the shin. Although the patient did not recall any obvious injury or trauma prior to the appearance of the ulcer, he did recall experiencing a sudden onset of pain at the time.

As a self-employed chef running his own restaurant and being the main wage earner in his household, he felt significant pressure to continue working and ignored the ulcer until it became debilitating. He then presented to his physician who commenced him of regular analgesics for pain management and a course of antibiotics (ciprofloxacin) due to the purulent malodourous exudate, along with hydrogen peroxide dressings. As there was no improvement to his ulcer, he was referred to the specialist wound clinic.

On presentation, the wound measured 5 cm x 3 cm. The ulcer was heavily colonised with a likely biofilm [Figure 6] and the patient still reported high levels of pain (scoring 10 on the visual analogue scale). This meant he was unable to tolerate compression bandaging, thus creating further complications of oedema to the affected limb.

The patient was commenced on NATROX with the intention of reducing infection, as well as reducing the pain experienced while stimulating wound healing. Having already used NATROX, the team at San Giovanni Addolorata Hospital in Italy was confident of the effectiveness and efficiency of the device and felt it was the most appropriate therapy for improving the patient's wound condition.

The use of the device also allowed the patient to regain some level of autonomy over his care,

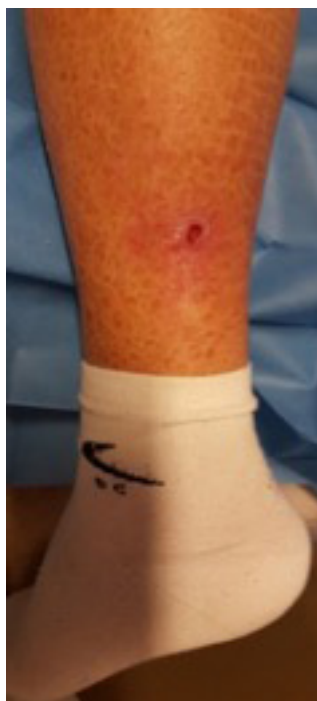

Figure 8. Significant reduction in size at day 47 of Natrox therapy.

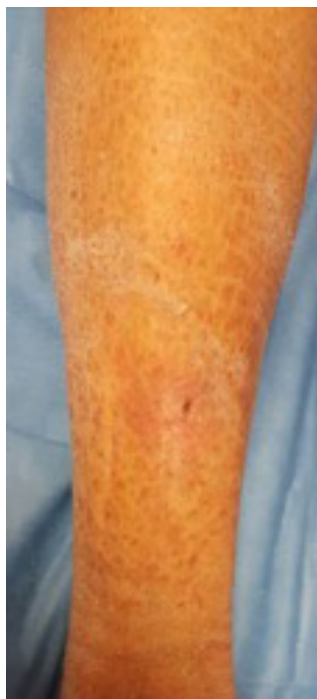


Figure 9. Day 65 almost healed – Natrox therapy discontinued.

owing to his involvement in the day-to-day management of the device. The ODS was applied directly on the wound bed, however, due to the high levels of exudate and the inability of the patient to tolerate compression bandaging, a non-adhesive polyurethane foam was used to cover the ODS, secured with a film dressing, and tubular bandage, the foam dressing helped to protect the periwound skin from maceration.

Within 4 hours of starting the device, the patient reported an improvement in his pain. The secondary dressing choice allowed for appropriate containment of the exudate levels and this allowed the dressing to remain in place for up to 4 days. At day 20 [Figure 7], the ulcer appeared much larger in area size, although the depth of the wound had reduced. As in the previous case, this increase in wound size is expected with NATROX therapy due to the autolytic debridement function of oxygen, however, the ulcer bed began to look healthier with active signs of granulation.

There was a reduction in the signs of infection and improvement in reported pain levels. The surrounding skin appeared much less inflamed, probably due to the reduction in exudate and oedema. After 47 days of therapy, there was significant reduction in size [Figure 8].

NATROX therapy continued for a total of 65 days, at which time the wound was deemed almost healed and stepped down to a dry dressing [Figure 9]. The condition of the patient's skin at closure was exceptional, with little or no evidence of scar tissue. Improving not just the speed of healing but also the quality of healing should reduce the chances of reoccurrence, which is high in chronic wounds. From a patient perspective, being able to return to work after a 6-month absence was not just economically beneficial to this patient but also helped psychological wellbeing.

### Discussion

When comparing these two cases, although the ulcers have a very different aetiology, they both share some common themes in terms of non-healing, pain and infection. Pain is a common symptom with any ulceration and, as a direct result of this pain, the stress response can lead to a cascade of physiological events that have a negative impact on wound healing (Woo, 2008). This stress response experienced by patients can cause overproduction of cortisol and catecholamines, which can alter the immune system and create further tissue hypoxia (Kiecolt-Glaser et al, 1995).

As previously discussed, NATROX reverses local hypoxia which, in turn, increases the cellular activity in that area. This includes the antibacterial

process that engulfs and destroys pathogens in the wound, increasing the autolytic debridement. The increase in this activity was evident in both ulcers resulting initially in increased wound area. This phase was quickly followed with evidence of healthy granulation tissue in the wound bed before a decrease in wound area size.

Encouraging patient concordance with wound care therapies is an important aspect in achieving wound healing. As seen in case 1, the patient's ulcer continued to deteriorate due to his refusal to stop wearing the shoes that caused the ulceration and his inability to tolerate NPWT due to the pain experienced.

Likewise, the patient in the second case had ignored the deterioration in his ulceration to the point where he began experiencing debilitating pain, which then made concordance with compression difficult. The use of NATROX encourages patient involvement as they have to change the battery on a daily basis and because the device is simple to use, patients may be suitable to be educated in the application of the device independently. Moore (2016) highlights that involving patients in their own care has a positive outcome on their experience and satisfaction with treatment, this can also lead to improved clinical and economical outcomes and this was certainly the case for these two patients.

The prevalence of chronic wounds in Italy in 2013 is reported to have been 2.8% of the population; of this total, chronic leg ulcers accounted for 65% (Global Data Report, 2015). The total annual spend for health care in Italy is €149bn, with wound care accounting for 4% of this total. Ulceration affects 2m people, lasting 78 days on average (Global Data Report, 2015).

The patients discussed in these cases both exceeded this 78-day average and, therefore, accounted for a large proportion of the wound care budget within their local healthcare authority. The evidence for increasing oxygen levels to aid wound healing is widely available and accepted (Sen, 2009), however, being able to access appropriate and easy methods of delivering oxygen has not existed, historically.

The two cases in this article provide evidence of how easy NATROX oxygen wound therapy is to incorporate into clinical practice and the positive and cost-effective outcomes it can have on chronic non-healing ulcers. Case 1 involved a non-healing wound present for 2 years and after only 35 days of treatment with NATROX, significant improvement was evident and the wound progressed on a healing trajectory. In terms of case 2, the ulcer had been non healing for 2.5 years and complete healing was seen within 65 days.

The need to adopt a more proactive approach for hard-to-heal and challenging wounds has long been identified. A recent round table report (Wounds International, 2018) further stressed the importance of this approach and highlighted a potential treatment algorithm of the use of portable topical oxygen. Prior to the commencement of NATROX therapy, the patients had received a combined total of 4 years of multiple therapies, all of which had had little impact for these patients. Identifying when to use oxygen therapy is key to improving clinical outcomes and associated costs.

WINT

## References

- Apollonio A, Antignani PL, Di Salvo M et al (2016) A large Italian observational multicentre study on vascular ulcers of the lower limbs (Studio Ulcere Vascolari). *Int Wound J* 13(1): 27–34
- Asmis R, Qiao M, Zhao Q (2010) Low flow oxygenation of full-excisional skin wounds on diabetic mice improves wound healing by accelerating wound closure and re-epithelialization. *Int Wound J* 7(5): 349–57
- Bishop A (2008) Role of oxygen in wound healing. *J Wound Care* 17(9): 399–402
- Davis SC, Cazzaniga AL, Ricotti C et al (2007) Topical oxygen emulsion: a novel wound therapy. *Arch Dermatol* 143(10): 1252–6
- Frye C, Blackman E, Moore C et al (2010) Topical wound oxygen therapy in the treatment of severe diabetic foot ulcers: a prospective controlled study. *Ostomy Wound Manage* 56(6): 24–31
- Global Data (2015) *MediPoint: Advanced Wound Dressings - Global Analysis and Market Forecasts*. Available at: <https://bit.ly/2QsuCMn> (accessed 18.11.2019)
- Gottrup F, Apelqvist J (2012) Present and new techniques and devices in the treatment of DFU: a critical review of evidence. *Diabetes Metab Res Rev* 28(Suppl 1): 64–71
- Howard MA, Asmis R, Evans KK, Mustoe TA (2013) Oxygen and wound care: A review of current therapeutic modalities and future direction. *Wound Repair Regen* 21(4): 503–11
- Kimmel HM, Grant A, Ditata J (2016) The presence of oxygen in wound healing. *Wounds* 28(8): 264–70
- Järbrink K, Gao N, Sönnergren H et al (2016) Prevalence and incidence of chronic wounds and related complications: a protocol for a systematic review. *Syst Rev* 5(1): 152
- Kaufmann H, Gurevich M, Tamir E et al (2018) Topical Oxygen therapy stimulates healing in difficult, chronic wounds: a tertiary centre experience. *J Wound Care* 27(7): 426–33
- Kiecolt-Glaser JK, Marucha PT, Malarkey WB et al (1995) Slowing of healing by physiological stress. *Lancet* 346(8984): 1194–6
- Kranke P, Bennett MH, Martyn-St James M et al (2015) Hyperbaric oxygen therapy for chronic wounds. *Cochrane Database Syst Rev* (6): CD004123
- Lindholm C, Searle R (2016) Wound management for the 21st century: combining effectiveness and efficiency. *Int Wound J* 13(Suppl 2): 5–15
- Mani R (2010) Topical oxygen therapy for chronic wounds: a report on the potential of Natrox™ a new device for delivering enriched oxygen to chronic wounds. *J Wound Technol* 9(1): 28–30
- Moore Z (2016) Patient empowerment in wound management. *Wound Essentials* 11(1): 32–5
- Posnett J, Franks PJ (2008) The burden of chronic wounds in the UK. *Nurs Times* 104: 44–5
- Rango A, Cavallaro E, Marsili D et al (2018) The epidemiological burden of chronic skin wounds in Italy. *Gazzetta Medica Italiana – Archivio Per Le Scienze Mediche* 177(4): 173–4
- Rodriguez PG, Felix FN, Woodley DT, Shim EK (2008) The role of oxygen in wound healing: a review of the literature. *Dermatol Surg* 34(9): 1159–69
- Said HK, Hijjawi J, Roy N et al (2005) Transdermal sustained-delivery oxygen improves epithelial healing in a rabbit ear wound model. *Arch Surg* 140(10): 998–1004
- Sen CK (2009) Wound healing essentials: let there be oxygen. *Wound Repair Regen* 17(1): 1–18
- Sen C (2019) Human wounds and its burden: an updated compendium of estimates. *Adv Wound Care* 8(2): 39–48
- Smith BM, Desvigne LD, Slade JB et al (1996) Transcutaneous oxygen measurements predict healing of leg wounds with hyperbaric therapy. *Wound Repair Regen* 4(2): 224–9
- Winfield B (2014) Topical oxygen and hyperbaric oxygen therapy use and healing rates in diabetic foot ulcers. *Wounds* 26(5): 39–47
- Woo KY (2012) Exploring the effects of pain and stress on wound healing. *Adv Skin Wound Care* 25(1): 38–44
- Wounds International (2018) *Consensus Round Table Meeting: Portable Topical Oxygen Therapy for Healing Complex Wounds*. Wounds International: London. Available at: <https://bit.ly/2PCNYht> (accessed 31.10.2019)
- Yu J, Lu S, McLaren AM et al (2016) Topical oxygen therapy results in complete wound healing in diabetic foot ulcers. *Wound Repair Regen* 24(6): 1066–72